



# Short Communications

---

## What is the Function of the Image Methods on Psychiatric Diseases?

- Sebastião David Santos-Filho and Roberto Levi Cavalcanti Jales

**Open Access**

**Volume 1**

**Issue 4**

Received Date: November 08, 2022

Accepted Date: December 04, 2022

Published Date: December 17, 2022

---

**Citation:** Sebastião David Santos-Filho and Roberto Levi Cavalcanti Jales. What is the Function of the Image Methods on Psychiatric Diseases?. ICARE. 2022;1(4):1017.

# What is the Function of the Image Methods on Psychiatric Diseases?

Sebastião David Santos-Filho<sup>1\*</sup> and Roberto Levi Cavalcanti Jales<sup>2,3</sup>

<sup>1</sup>Department of Bioscience, Federal University of Rio Grande do Norte, Brazil

<sup>2</sup>Department in Medicine, Federal University of Rio Grande do Norte, Brazil

<sup>3</sup>Clinica Nuclear de Natal, Tirol, Brazil

Received Date: November 08, 2022; Accepted Date: December 04, 2022; Published Date: December 17, 2022

**\*Corresponding author:** Sebastião David Santos-Filho, Department of Bioscience, Federal University of Rio Grande do Norte, Natal, Brazil, E-mail: sdavidsfilho@gmail.com

**Citation:** Sebastião David Santos-Filho and Roberto Levi Cavalcanti Jales. What is the Function of the Image Methods on Psychiatric Diseases?. ICARE. 2022;1(4):1017.

**Copyright © 2022 Sebastião David Santos-Filho.** This is an open access article published under the Creative Commons Attribution License, which permits unrestricted use, distribution, and reproduction in any medium, provided the original work is properly cited.

## Abstract

It is known that the named mental diseases are in reality cerebral diseases and as it is, needed of exploration of this organ with image methods. The question that remains obscure is about the function of the studies organs are diminished? Or increased? Trying to answer these questions we purposed an elucidative text with some images obtained by nuclear medicine to avoid a new era in psychiatric diagnostic.

**Keywords:** Mental diseases; Nuclear medicine images; Psychiatry; HMPAO; Technetium-99m

## Introduction

It is known that the named mental diseases are in reality cerebral diseases and as it is, needed of exploration of this organ with image methods. When the symptomatology predominant is neurologic (paralyse, dementia, stroke, etc) the option still defined by methods that express the cerebral anatomy, of the type of Computed Tomography (CT) or Magnetic Resonance (MR). These image methods express with details the organs anatomy.

The question that remains obscure is about the function of the studies organs are diminished? Or increased? Taken for

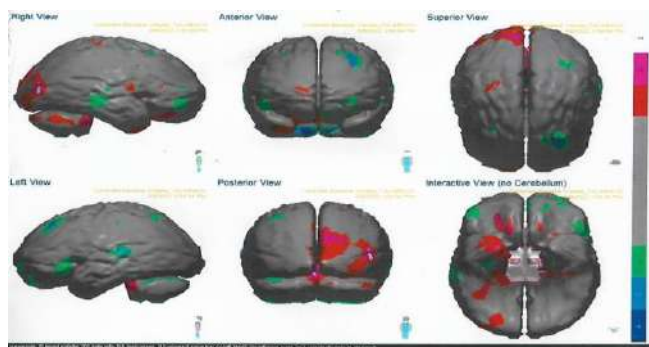
example, the thyroid gland, that could be with hypo or hyperthyroidism and its anatomy still preserved. Following this thought about our brain stay the importance of study the cerebral function, in this case, start by perfusion [1,2].

## The Cerebral Perfusion as Indicative of Organ Function

All the tissues and cells need of the blood arise and of blood flow-out, as primordial condition, but a second step, the passage of the blood to the interior of the cells is other phenomenon, the called blood perfusion. This phenomenon could have distinct velocities: increase or diminish. The cellular metabolism is important regulator factor, giving the perfusion to the brain study, seen that it translates the functional state of the neurons. The detail more relevant is that a part of the neurons can be working of diminish form (hypoperfusion) or can be working of increase form (hyperperfusion) [1].

## How to Explore the Perfusion

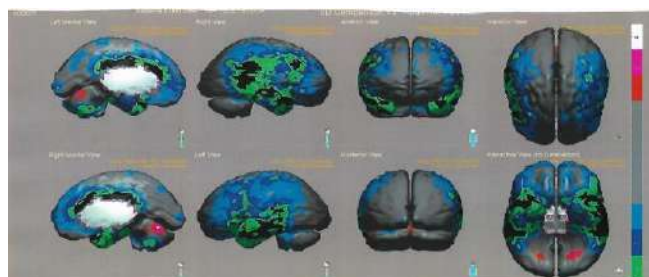
It was seen that anatomic methods (CT, MR) evaluate the anatomic structures. The Nuclear Medicine (NM) is the method that make tissue perfusion images through the Cerebral Perfusion Scintigraphy (CPS) realized through the junction of a tracer and a radioactive element, in the case, HMPAO + Technetium-99m. The CPS is a simple and informative process, it will be the radiotracer (HMPAO-Tc-99m) injected venous via, in thi]ke 20 mCi activity with follow exposition to the gamma-camara devices. The normal images (Figure 1) showed more fixation to occipital level, translating the visual physiological process [1].



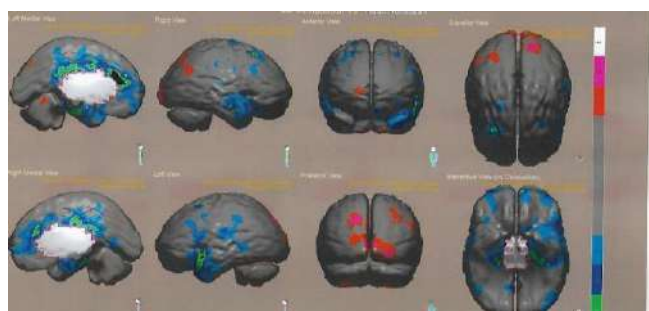
**Figure 1:** Showing the normal images where more fixations had to occipital level significant the visual physiological process.

**The Value in Psychiatry**

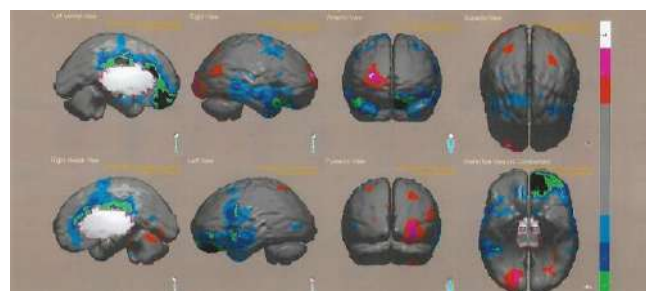
Starting of the firstly that the psychiatric disease is in the human brain and that the perfusion express the cellular metabolic activity, finding diminished in the Alzheimer disease cases (Figure 2), cognitive deficit (Figure 3), stroke (Figure 4). In cases of bipolarity has cortical diffuse hyper perfusion (Figure 5). Patients with Attentional Deficit (AD) has Frontal Hyper Perfusion (Figure 6).



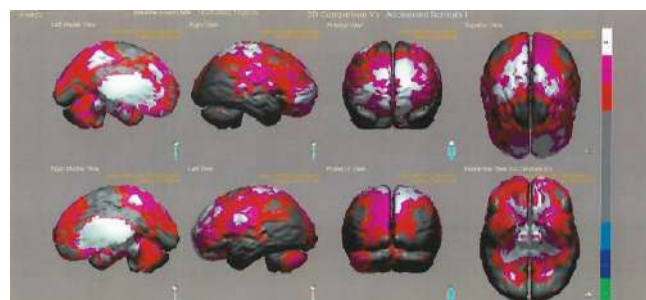
**Figure 2:** The perfusion founded diminished (blue colour) in the Alzheimer disease cases.



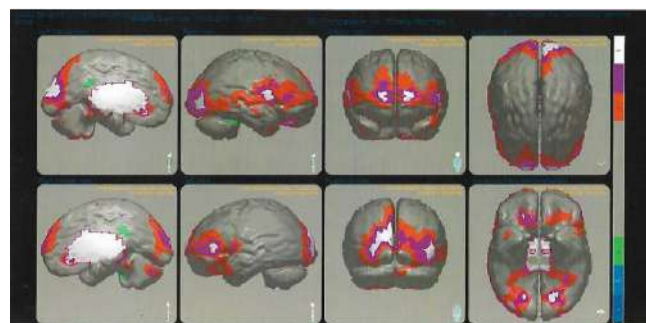
**Figure 3:** The perfusion of cognitive deficit presenting blue colour in the cingulate gyrus.



**Figure 4:** The perfusion of stroke presenting dark blue colour in the left inferior frontal lobe.



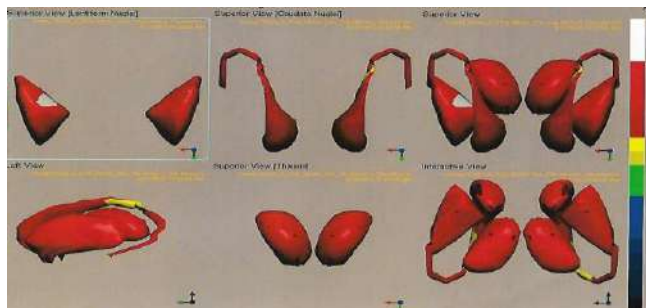
**Figure 5:** The perfusion in cases of bipolarity presented cortical diffuse hyper perfusion (red and white colour).




**Figure 6:** The perfusion in patients with attentional deficit showing frontal hyper perfusion (red and white).

**What do the Brain Base Nucleus in the Humans?**

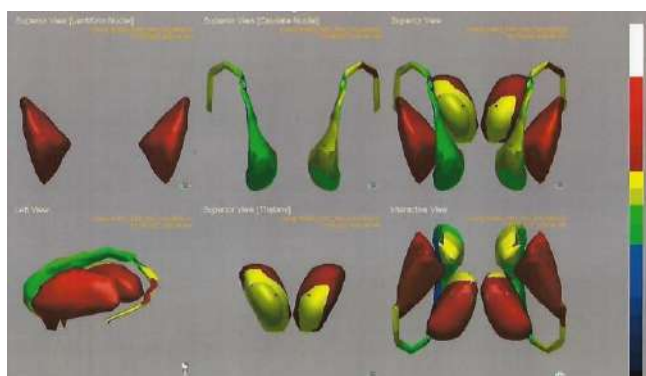
Defined as “black” structures inside of brain white area, distributed of double forms, the thalamus, caudate nucleus, and lentiform nucleus, by example, participate of vary neuropsychic circuits. They are essentials to functional normality. The nuclear medicine has anemphasis role to evaluate the ganglionate perfusion (also called nuclear) [3,4], where the images are normal (Figure 7), could be increased (Figure 8) or diminished (Figure 9) justifying the psychic symptomatology of the patients.



**Figure 7:** Normal Ganglionate perfusion showing all red colour.



**Figure 8:** Increased Ganglionate perfusion showing white colour in lentiform nucleus.



**Figure 9:** Diminished Ganglionate perfusion showing green and yellow colour in the caudate and thalamus nucleus.

### Conclusion

The cellular function study could be related to the perfusion phenomenon, and the NM evaluates with emphasis this process. It is crescent the notion of that the mental disease is a brain disturb, and as such its perfusion must be investigated. It is the psychiatry based in brain images.

### Declarations

- There are no needs for ethical approval to this work because it is a descriptive work.

- We consenting for publication in this journal.
- All data and figures used in this work are of the data bank of the Clínica Nuclear de Natal.
- No competing interest there are in this work.
- No funding was used to do this.
- All authors have the same contribution to do this work.
- We thanks to Clínica Nuclear de Natal for give us the material to do this work.

### References

1. Saha G. Fundamentals of Nuclear Pharmacy. New York: SpringerVerlag; 2018.
2. Perkins A, Frier M. Nuclear Medicine in Pharmaceutical Research. London: Taylor & Taylor Ltd; 1999.
3. Jales RLC, Santos-Filho SD. Approaches of nuclear medicine in psychiatry: perfusion against function, the psychiatric question. EC Clin Med Case Rep. 2020;3(3):1-5.
4. Amen D, Trujillo M, Newberg A, Willeumier K, Tarzwell R, Wu JC, et al. Brain SPECT Imaging in Complex Psychiatric Cases: An Evidence-Based, Underutilized Tool. Open Neuroimag J. 2011;5:40-8.



<https://ijcasereports.com/>